

The Tooth with a Twist—A Case of Tooth Flexion.

Geon Pauly^{1*}, Roopashri Rajesh Kashyap², Raghavendra Kini³, Prasanna Kumar Rao⁴, Gowri P Bhandarkar² and Preethi A Poonja⁵

¹Postgraduate Student, Department of Oral Medicine and Radiology, A.J Institute of Dental Sciences, Kuntikana, Mangaluru, Karnataka, India

²Reader, Department of Oral Medicine and Radiology, A.J Institute of Dental Sciences, Kuntikana, Mangaluru, Karnataka, India

³Professor and Head, Department of Oral Medicine and Radiology, A.J Institute of Dental Sciences, Kuntikana, Mangaluru, Karnataka, India

⁴Professor, Department of Oral Medicine and Radiology, A.J Institute of Dental Sciences, Kuntikana, Mangaluru, Karnataka, India

⁵Assistant Professor, Department of Oral Medicine and Radiology, A.J Institute of Dental Sciences, Kuntikana, Mangaluru, Karnataka, India

***Corresponding Author:** Geon Pauly N, Postgraduate student, Department of Oral Medicine and Radiology, A.J Institute of Dental Sciences, Kuntikana, NH-66. Mangaluru. PIN- 575004, Karnataka, India.

Received: February 25, 2018; **Published:** March 10, 2018

Abstract

Dilaceration is defined as a deviation or bend in the linear relationship of the crown of a tooth in relation to its root. Although this kind of an alteration is relatively uncommon and also completely asymptomatic, it does pose a number of diagnostic, management, and prognostic challenges to dental practitioners.

Keywords: Dilaceration; Flexion; Exodontia; Root Canal Treatment

Volume 2 Issue 5 March 2018

© All Copy Rights are Reserved by Geon Pauly N., *et al.*

Introduction

In 1848, Tomes was the first to coin the term dilaceration, who defined the phenomenon as the forcible separation of the cap of the developed dentine from the pulp while the development of the dentine is still under progress. In time, it was defined as an angulation or deviation or sharp bend or curve in the linear relationship of the crown of a tooth to its root [1]. This definition discriminates dilaceration from flexion which denotes a smooth physiologic or abnormal curvature of the root [2]. Hereby, we present a case of tooth an unusual curved morphology.

Case Report

A 29-year-old medically fit male patient visited our department with a chief complaint of pain upper front tooth region since 1 week. His medical, dental and family histories were non-contributory. On intra-oral examination, there was an extensive deep decay on the lingual surface of right maxillary central incisor which was tender to palpation. A provisional diagnosis of apical periodontitis was given and patient was advised for an IOPA. Radiographic image revealed mid-way the root morphology there was an unusual morphological curvy tilt towards the distal side [Figure 1]. The periapical picture confirmed our provisional diagnosis and the patient was referred to department of endodontics for root canal treatment.

Citation: Geon Pauly N., *et al.* "The Tooth with a Twist—A Case of Tooth Flexion." *Oral Health and Dentistry* 2.5 (2018): 469-471.

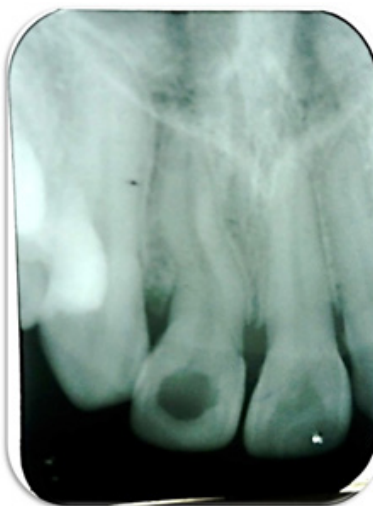

Figure 1: Flexion of root in relation to 11.

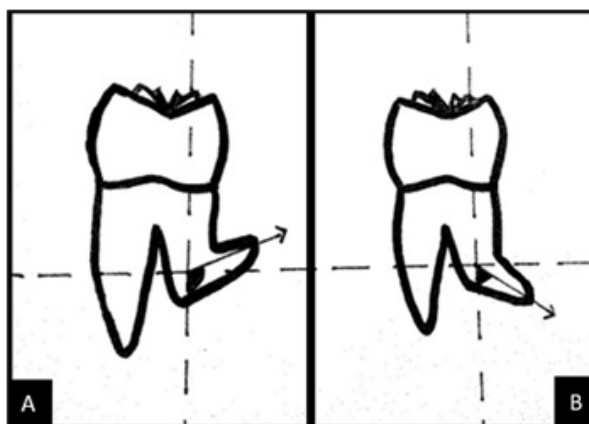


Figure 2: Diagrammatic Picture: A - Dilaceration. B - Flexion.

Discussion

In 1971, Andreasen, *et al.* defined dilaceration as the abrupt deviation of the long axis of the crown or root portion of the tooth, due to a traumatic non-axial displacement of already formed hard tissue in relation to the developing soft tissue [3]. Dilaceration and flexion refer to an angulation that may occur anywhere along the length of the tooth; crown, amelo-cemental junction, along the root, or by only involving the apex of the root [4]. Dilaceration and flexion have been considered to originate from traumatic displacement of already formed hard tissue in relationship to the developing soft tissue [5]. However, this pathogenesis has been questioned and it has been alternatively proposed that the deformity exists due to the ectopic development of the tooth germ rather than as a result of trauma [6]. Nonetheless, trauma is still accepted as one possible cause, particularly in the anterior region. To diagnose dilacerations and flexion of the root a radiographic examination is mandatory. The direction of radiographically evaluated dilacerations of roots can be read in 2 planes and categorized as mesial, distal, or orofacial [7].

A tooth can be recognized to have mesial or distal root dilaceration if there is a deviation of 90-degree or more from the normal long axis of the tooth. Likewise, it is termed as flexion if the deviation is less than 90-degree [Figure 2] [8]. Diagnosing root dilacerations/flexion before endodontic treatment is an important objective in gaining control as endodontic instruments tend to curve in the root canals. A frequent error in endodontic procedure is the failure to maintain root canal curvature, resulting in ledging, apical cavitation, perforation, and instrument breakage. Likewise, it can be a challenge in cases where in the tooth is indicated for extraction [9].

Conclusion

“Abnormal is so common, that it’s practically normal.” were the words once told by noted science-fiction author Cory Doctorow. For developmental defects like tooth flexion or dilacerations, it kind of holds true, for these conditions are completely asymptomatic and normal to have. Nevertheless, when a treatment need is indicated in such tooth, dentist needs to be aware of the challenge at hand, for it will be a test of the dentists’ dexterity and decision making at large.

References

1. Topouzelis N, *et al.* “Dilaceration of maxillary central incisor: a literature review”. *Dental Traumatology* 26.5 (2010): 427-433.
2. Jafarzadeh H and Abbott PV. “Dilaceration: review of an endodontic challenge”. *Journal of Endodontics* 33.9 (2007): 1025-1030.
3. Andreasen JO, *et al.* “Textbook and color atlas of traumatic injuries to the teeth”. *Oxford: Blackwell Munksgaard* (2007): 542–576.
4. Malcic A, *et al.* “Prevalence of root dilaceration in adult dental patients in Croatia”. *Oral Surgery, Oral Medicine, Oral Pathology, Oral Radiology, and Endodontology* 102.1 (2006): 104-109.
5. Prabhakar AR, *et al.* “Duplication and dilaceration of a crown with hypercementosis of the root following trauma: a case report”. *Quintessence International* 29.10 (1998): 655-677.
6. Chadwick SM and Millet D. “Dilaceration of a permanent mandibular incisor. A case report”. *British Journal of Orthodontics* 22.3 (1995): 279-281.
7. Sawamura T, *et al.* “Impacted teeth in the maxilla: usefulness of 3D Dental-CT for preoperative evaluation”. *European Journal of Radiology* 47.3 (2003): 221-226.
8. Standerwick RG. “A possible etiology for the dilaceration and flexion of permanent tooth roots relative to bone remodeling gradients in alveolar bone”. *Dent Hypotheses* 5.1 (2014): 7-10.
9. Walton RE and Torabinejad M. *Principles and Practice of Endodontics*. 2nd ed. Philadelphia: WB Saunders; (1996): 330-332.

Submit your next manuscript to Scientia Ricerca Open Access and benefit from:

- Prompt and fair double blinded peer review from experts
- Fast and efficient online submission
- Timely updates about your manuscript status
- Sharing Option: Social Networking Enabled
- Open access: articles available free online
- Global attainment for your research

Submit your manuscript at:

<https://scientiaricerca.com/submit-manuscript.php>